

Otterbein University

Digital Commons @ Otterbein

Nursing Student Class Projects (Formerly MSN)

Student Research & Creative Work

Summer 8-1-2016

Pathophysiology-Stevens-Johnson Syndrome/Toxic Epidermal Necrolysis

Douglas M. Klein

Otterbein University, douglas.klein@otterbein.edu

Follow this and additional works at: https://digitalcommons.otterbein.edu/stu_msn



Part of the [Nursing Commons](#)

Recommended Citation

Klein, Douglas M., "Pathophysiology-Stevens-Johnson Syndrome/Toxic Epidermal Necrolysis" (2016).
Nursing Student Class Projects (Formerly MSN). 182.
https://digitalcommons.otterbein.edu/stu_msn/182

This Project is brought to you for free and open access by the Student Research & Creative Work at Digital Commons @ Otterbein. It has been accepted for inclusion in Nursing Student Class Projects (Formerly MSN) by an authorized administrator of Digital Commons @ Otterbein. For more information, please contact digitalcommons07@otterbein.edu.

Stevens-Johnson Syndrome and Toxic Epidermal Necrolysis

Doug Klein RN, BSN

Otterbein University, Westerville, Ohio

Introduction

Stevens-Johnson Syndrome (SJS) and Toxic Epidermal Necrolysis (TEN) are rare, cutaneous, severe, drug-induced hypersensitivity reactions marked by widespread inflammation of the epidermis, ending in necrosis and the eventual sloughing of tissue. First described in 1922 by pediatricians Albert Stevens and Frank Johnson, both diseases are believed to be as a result of the same disease process. They are the most serious of all drug-related hypersensitivity reactions which result in hospitalization (Ferrandiz-Perez & Garcia-Patos, 2013).

As a critical care nurse caring for a variety of trauma patients, it is crucial that staff is aware of potentially serious medication reactions. Some of the most serious of these start out with vague symptoms and may appear benign. However, some are very serious and potentially fatal.

Signs and Symptoms

Early signs/symptoms:

- Fever, malaise, fatigue and mucosal lesions, headache, bleeding

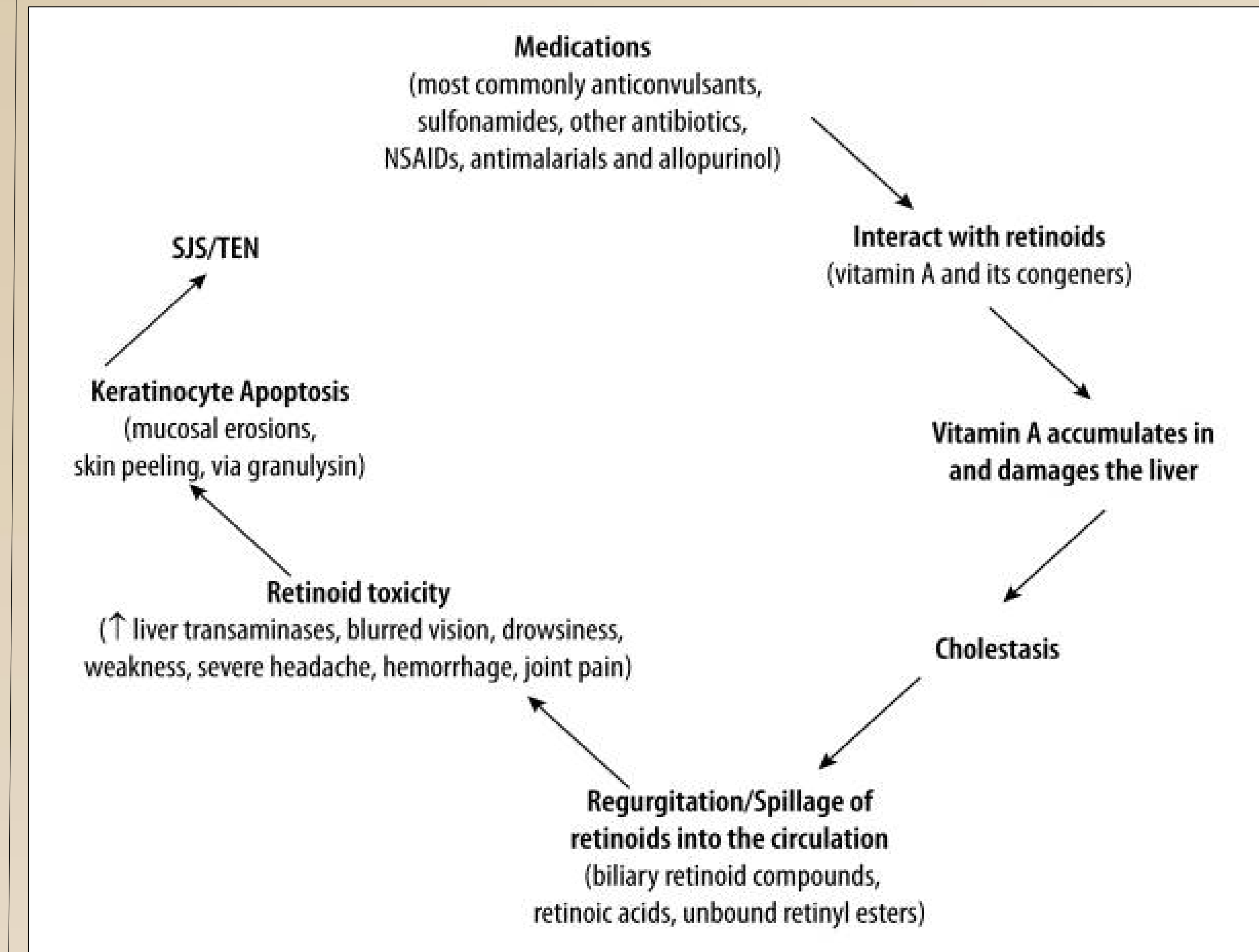
Later signs/symptoms:

- Marked erythema of skin leading to papules, vesicles and necrosis. These start on the face neck and anterior trunk and may extend over the entire surface of the skin.
- Mucosal involvement, including ocular, GI, GU, genital and upper and the epithelial cells of the lower respiratory tree. These areas are associated with heavy bleeding , scarring and long-term complications.

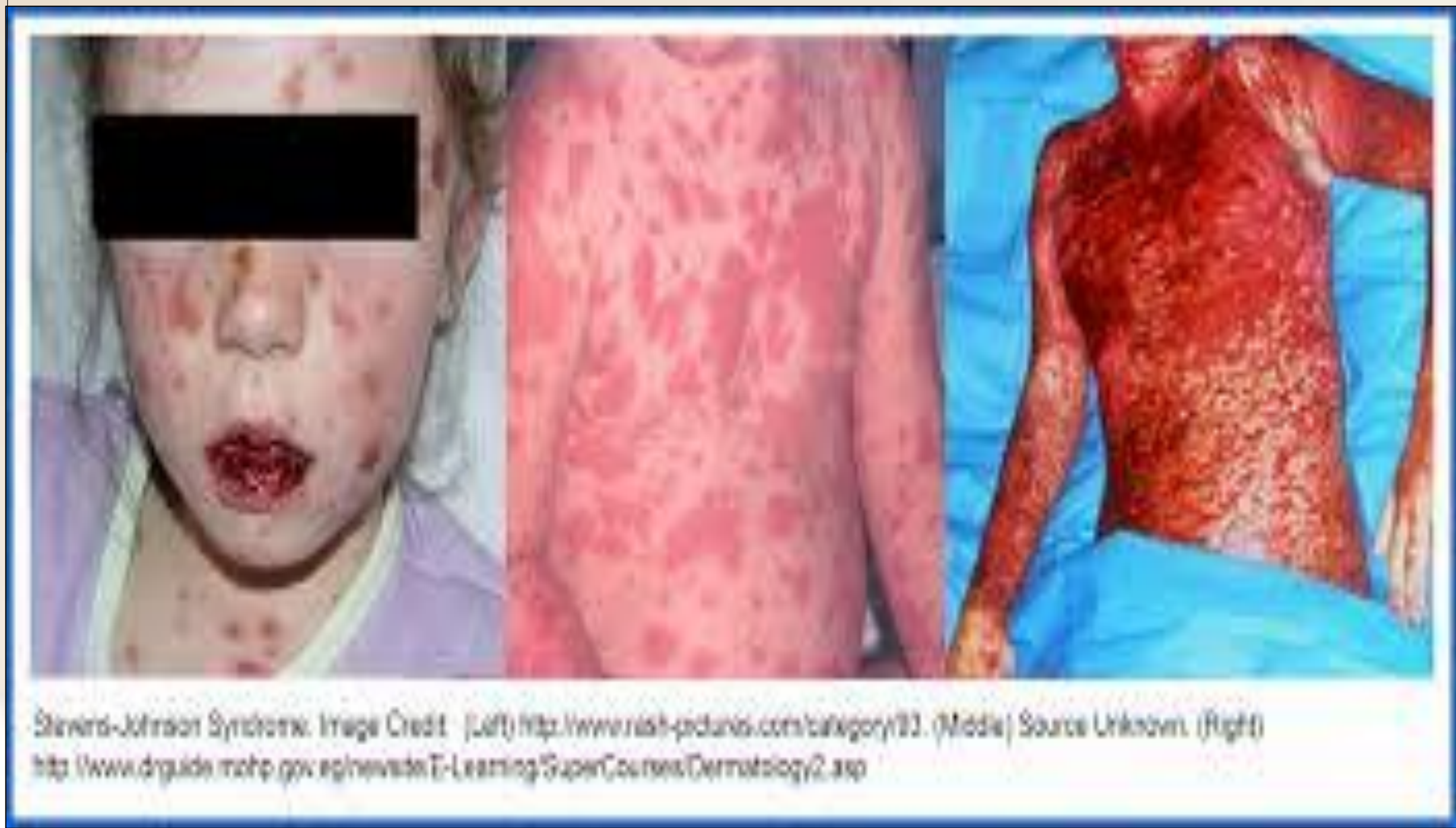Statistics

Disease	TBSA %	Mortality	Incidence/million
SJS	<10%	5%	2-6
TEN	>30%	30%	0.2-1.2

(Mawson et al., 2015) (>10%, <30% is considered to be mixed SJS/TEN disease) (TBSA-total body surface area)



Retinoid and Granulysin-mediated hypothesis Of Stevens-Johnsons Syndrome/Toxic Epidermal Necrolysis (SJS/TEN) (Mawson, et al, 2015)



Progression of SJS/TEN

Pathophysiology-Overview

SJS/TEN disease has long been presumed to appear as a result of an immune-mediated response to certain drug metabolites, although the exact mechanism of action has been poorly understood. Evidence has established a genetic predisposition for illness to various Asian populations, leading to FDA recommendations for pre-therapy genetic testing. Additional research has focused on the effects Vitamin A derivatives have on the disease process.

Pathophysiology

SJS/TEN is marked by the widespread eruption of macules and papules which eventually lead to skin necrosis and sloughing. Until recently, SJS/TEN has been thought to be an idiopathic illness. Research seeking to clarify the genesis of the illness has found that morbidity can be a result of a genetic predisposition to a drug hypersensitivity reaction. Genetic research has identified several combinations of Alleles and medications which when combined, increase the risk of illness. Further research has sought understanding into the disease pathophysiology. In a paper published by Mawson, Eriator and Karre (2015), the authors theorize that disease occurs when a drug metabolite damages the liver, the organ responsible for storage of Vitamin A, causing free-retinoid molecules to spill into the circulation creating an acute, systemic Vitamin A toxicity. Granulysin, a cytotoxic protein produced in massive quantities by both CD8+ T-Lymphocytes and natural killer cells is the most prevalent molecule found in SJS/TEN blisters. Granulysin is believed to act as a cytokine for destructive retinoid molecules (such as retinoic acid), combined together are believed to be responsible for keratinocyte apoptosis seen in SJS/TEN. As keratinocytes die off, the epidermis becomes detached from the dermis ending in tissue necrosis and sloughing (Teo & Walsh, 2016). Although not fully understood, the authors theorize that CD8+ T-cells become hyperactive when exposed to extreme levels of retinol and overproduce Granulysin. Granulysin then attracts retinoic acid which are both cytotoxic and together cause keratinocytes to die off. Keratinocytes make up 90% of the cells in the epidermis.

Many classes of medications have been linked to SJS/TEN, including anticonvulsants, antibiotics, NSAIDS, corticosteroids and allopurinol. These medications increase circulating retinoid levels, either through hepatic release as a result of liver injury, or through the inhibition of metabolism which leads to higher circulating retinol derivatives, such as retinoic acid, a powerful cell-lysing agent (Mawson, Eriator, & Karre, 2015). Hepatic injury could explain the extended prodromal illness seen in this disease as patients often present with vague illness which typically lasts for over a week prior to the onset of the more identifiable rash.

Implications: Pathophysiology

Understanding pathophysiology is key for treating and limiting the destructive mechanism for disease. Provided that retinol toxicity is involved with SJS/TEN, plasmapheresis could be used to reduce circulating levels and mitigate the destructive effects which retinol contributes in this disease. Plasmapheresis has been shown in small samples to reduce mortality versus typical treatment for patients with SJS/TEN (Mawson, 2015).

Genetic predispositions have been positively established for people of Asian descent who carry the HLA-B1502 Allele when exposed to Carbamazepine. The FDA recommends genetic testing prior to starting Asian patients on Carbamazepine therapy (Tangamornsukan, Chalyakunapruk, Somkrua, Lohitnavy, & Tassaneeyakui, 2013). Studies have also linked a higher than normal incidence of SJS/TEN within the Indian population, particularly is they are HIV-positive (Patel, Barvaliya, Sharma & Tripathi, 2013). HLA-A3101 has recently been identified as a phenytoin-associated risk among Japanese and Europeans (Pirmohamed et al., 2011). Understanding genetic associations can help healthcare providers the mitigate risk through pre-therapy testing.

Nursing: Implications:

Rapid identification of disease is crucial for patients suffering from SJS/TEN as removal of the offending medication is critical for mitigating the effects of the illness. Nursing should familiarize themselves with the symptoms and signs of progression as illness may advance quickly from SJS to TEN in as few as twelve hours (Poulson, Nielsen, & Poulsen, 2013).

- Nursing should be watchful for signs or symptoms of decompensation due to respiratory failure or sepsis.
- Pain management and the use of conscious sedation, especially during debridement and dressing changes will improve healing and health outcomes.
- Treatment is best done in a specialized burn center.
- The nurse should seek to coordinate a multi-disciplinary team approach(Cooper, 2012).
- Long-term restrictive pulmonary disease is frequently seen with SJS/TEN and patients will often require long-term use of bronchodilators (British Journal of Medicine, 2015).

Conclusions:

Although SJS/TEN has been recognized illness for decades, recent advancements in genetics have identified strong predispositions to certain drug reactions, helping guide prescribers prior toward safe and effective treatment. Patients at risk should be tested for susceptibility before starting therapy. The use of plasmapheresis should be studied further to determine whether limiting free-retinoid compounds could mitigate the damage caused by disease.

References

- Chantaphakul, H., Sanon, T., & Klaewsongkram, J. (2014, July 31). Clinical characteristics and treatment outcome of stevens-johnson syndrome and toxic epidermal necrolysis. *Experimental and Therapeutic Medicine*, 10, 519-524. <http://dx.doi.org/10.3892/etm.2015.2549>
- Cooper, K. L. (2012, August). Drug reaction, shin care, skin loss. *Critical Care Nurse*, 32(4), 52-59. <http://dx.doi.org/10.4037/ccn2012340>
- Editorial. (2015). *British Journal of Dermatology*, 172, 312. <http://dx.doi.org/10.1111/bjd.13631>
- Fallon, M. J., & Heck, J. N. (2015). Fatal stevens-johnson syndrome/toxic epidermal necrolysis induced by allopurinol-rituximab-bendamustine therapy. *Journal of Oncology Pharmacology Practice*, 21(5), 388-392. <http://dx.doi.org/10.1177/1078155214533368>
- Ferrandiz-Perez, C., & Garcia-Patos, V. (2013). Review: A review of causes of Stevens–Johnson syndrome and toxic epidermal necrolysis in children. *Archives of Disease in Childhood*, 98, 998-1003. <http://dx.doi.org/10.1136/archdischild-2013-303718>
- Mawson, A. R., Eriator, I., & Karre, S. (2015, January 12). Stevens-johnson syndrome and toxic epidermal necrolysis (SJS/TEN): could retinoids play a causative role? *Medical Science Monitor*, 21, 133-143. <http://dx.doi.org/10.12659/MSM.891043>
- Patel, T. K., Barvaliya, M. J., Sharma, D., & Tripathi, C. (2013, May-June). A systematic review of the drug-induced stevens-johnson syndrome and toxic epidermal necrolysis in indian population. *Indian Journal of Dermatology*, 79(3), 389-398. <http://dx.doi.org/Retrieved from>
- Pirmohamed, M., Friedmann, P. S., Molokhia, M., Loke, Y. K., Smith, C., Phillips, E., ... Shear, N. H. (2011, March). Phenotype standardization for immune-mediated drug induced skin injury. *Nature Publishing Group*, 89(6). <http://dx.doi.org/10.1038/clpt.2011.79>
- Poulson, V. O., Nielsen, J., & Poulsen, T. D. (2013, July 28). Rapidly developing toxic epidermal necrolysis. *Case Reports in Emergency Medicine*, 1-4. <http://dx.doi.org/10.1155/2013/985951>
- Tangamornsukan, W., Chalyakunapruk, N., Somkrua, R., Lohitnavy, M., & Tassaneeyakui, W. (2013, September). Relationship Between the HLA-B*1502 Allele and Carbamazepine-induced stevens-johnson syndrome and toxic epidermal necrolysis systematic review and meta-analysis. *JAMA-Dermatol*, 149(9), 1025-1032. <http://dx.doi.org/10.1001/jamadermatol.2013.4114>
- Teo, Y. X., & Walsh, S. A. (2016). Severe adverse drug reactions. *Clinical Medicine*, 16(1), 79-83. Retrieved from <http://ezproxy.otterbein.edu/login?url=http://search.ebscohost.com/login.aspx?direct=true&db=a9h&AN=112724795&site=eds-live&scope=site>

