

Otterbein University

## Digital Commons @ Otterbein

---

Nursing Student Class Projects (Formerly MSN)

Student Research & Creative Work

---

Summer 7-2016

### Infective Endocarditis Related to IV Drug Abuse

Jasmine D. Branch

Otterbein University, [jasmine.branch@otterbein.edu](mailto:jasmine.branch@otterbein.edu)

Follow this and additional works at: [https://digitalcommons.otterbein.edu/stu\\_msn](https://digitalcommons.otterbein.edu/stu_msn)



Part of the [Nursing Commons](#)

---

#### Recommended Citation

Branch, Jasmine D., "Infective Endocarditis Related to IV Drug Abuse" (2016). *Nursing Student Class Projects (Formerly MSN)*. 136.

[https://digitalcommons.otterbein.edu/stu\\_msn/136](https://digitalcommons.otterbein.edu/stu_msn/136)

This Project is brought to you for free and open access by the Student Research & Creative Work at Digital Commons @ Otterbein. It has been accepted for inclusion in Nursing Student Class Projects (Formerly MSN) by an authorized administrator of Digital Commons @ Otterbein. For more information, please contact [digitalcommons07@otterbein.edu](mailto:digitalcommons07@otterbein.edu).

# Infective Endocarditis Related to IV Drug Abuse

Jasmine Branch RN  
Otterbein University, Westerville, Ohio

## Introduction

Illicit drug abuse amongst youth and adults in the United States continues to rise. In 2014, the U.S. had the highest rate of deaths due to drug overdose (Centers for Disease Control and Prevention, 2015). One common way people abuse drugs today are intravenously (IV), this route works fast and can cause an "immediate high". These drugs are often drawn up in a syringe and then injected into a vein. People often inject heroin, cocaine, prescription opiates and several other illegal drugs. Needles are often shared amongst others, or re-used, leading to increased exposure to infectious diseases.

The use of IV drugs can lead to serious health issues such as: cellulitis, hepatitis, HIV, sepsis, abscesses, pulmonary emboli, and many other conditions. Infective endocarditis is a disease commonly related to IV drug abuse, and is often seen on this nurse's unit. Infective endocarditis occurs when bacteria or fungi enters the blood stream and often infects an individual's heart valves (Peirce, Calkins, Thornton, 2012). Infective endocarditis can be life-threatening and requires aggressive medical treatment. Treatment often includes long term antibiotics, frequent blood monitoring, drug cessation and sometimes heart valve surgery. After treatment these patients have to really consider making lifestyle changes to improve their health and overall quality of life.

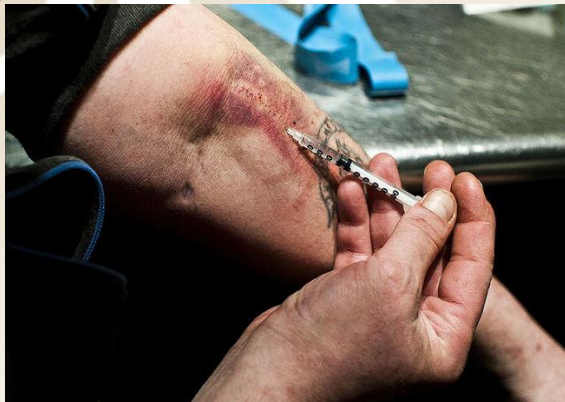

Figure 1. (Agar, 2013)

## Signs and Symptoms

IE may be classified as acute, sub-acute or chronic (McCance & Huether, 2014). Diagnosis may be difficult due to clinical manifestations that correspond with multiple organ systems: CNS, bones, joints, renal, pulmonary, or eyes (McCance & Huether, 2014).

- Night sweats
- Cardiac murmur
- Petechial lesions (skin, conjunctiva, oral mucosa)
- Osler nodes
- Janeway lesions
- Weight loss
- Chest pain
- Back pain

## Frequent Drugs Injected

- Heroin
- Cocaine
- Fentanyl
- Prescription Opioids (oxycodone, morphine, hydrocodone)

## Pathophysiology

While injecting drugs intravenously bacteria can enter the bloodstream and microorganisms can travel to the heart (McCance & Huether, 2014). Endothelial damage may cause a release of cytokines, adhesion molecules are then expressed and tissue factor activity rises, resulting in bacterial adhesions (Evans & Gammie). Bacterial adhesions on the valve cause an inflammatory response where monocytes react to the release of cytokines which then leads to ulceration, destruction of tissue, and fibrotic scarring within the valve (Evans & Gammie, 2011). The tissue then begins repairing itself excessively, causing vegetation to the heart valves (Evans & Gammie, 2011). The coagulation cascade is activated by tissue factor and platelets are then attracted, which is an element to vegetation (Evans & Gammie, 2011). As the vegetation increases, bacteria continuously binds and proliferates within the valve (Evans & Gammie, 2011).

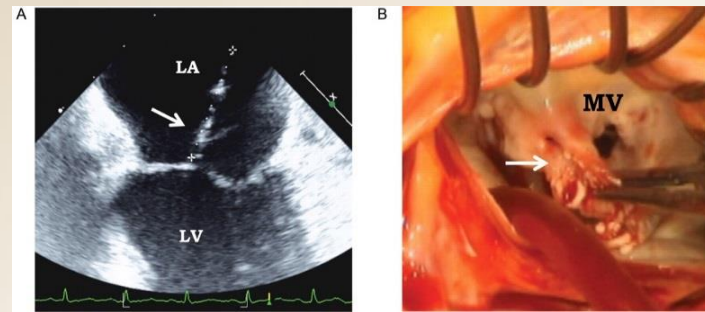


Figure 2. (Habib et al., 2010)

## Significance of Pathophysiology

IE is a serious medical condition and can be life threatening. Although there have been medical advancements, the morbidity and mortality rates of IE are still high (Sabe, Shrestha, Menon, 2013). Treatment of IE may include long term use of IV antibiotics for several weeks. If the heart valves are severely damaged, the valve may need to be replaced via open heart surgery. IE can result from several conditions other than IVDA. Other causative factors may include: congenital lesions, acquired valve disease, implants (pacemakers, defective valves), heart transplant, long term indwelling intravenous catheters, or dental procedures (McCance & Huether, 2014). Different pathogenesis may occur with each condition. The causative factors mentioned above may not all be 100% preventable, however, IE caused by IVDA is 100% preventable. IVDA accounts for approximately 9.8 % of the risk factors for IE (Peirce, Calkins, & Thornton, 2012). Choosing not to abuse drugs would drastically lower ones' risk of developing endocarditis.

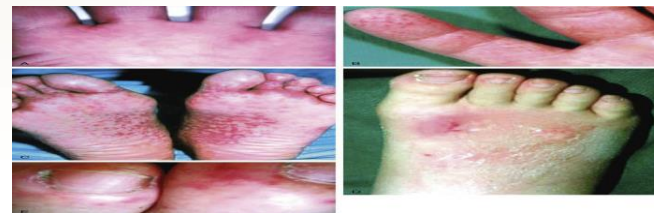


Figure 3. (Keys, 2010)

## Implications of Nursing

### Care

Patients diagnosed with IE are often hospitalized for close management during the initial treatment process. Nurses have a vital role in caring for these patients while in the hospital, rehab facilities, and even in the home setting. Below lists a few nursing implications:

- Monitoring vital signs
- Administration of antibiotics (IV/PO)
- Post-operative care (if surgery indicated)
- Encourage drug cessation, lifestyle modifications
- Education

### Conclusion

IE can be a major complication for IVDA. IE often needs aggressive medical treatment, and sometime surgical treatment. Individuals who abuse drugs with IE need to consider lifestyle modifications to prevent further infections and promote a healthier life. With the climbing rates of drug abuse within the U.S. today, we may start to see a rise in patients with IE and other drug related deaths. As health professionals it is important for us to continue to encourage drug cessation, support those trying to quit, and always educate our community the importance of not using drugs.

## Additional Resources

Agar, J. (2013) Not so safe injection site. Retrieved from <http://www.torontosun.com/2013/07/08/not-so-safe-injection-site>

Habib, G., Badano, L., Tribouilloy, C., Villacosta, I., Zamorano, J.L., Galderisi, M., Aukhus, S. (2010). Recommendations for the practice of echocardiography in infective endocarditis. Retrieved from <http://ehjcm.oxfordjournals.org/content/11/2/202>

Keys, T. (2010). Retrieved from <http://www.clevelandcliniced.com/medicalpubs/disease-management/infectious-disease/infective-endocarditis/>

## References

- Bogabathina, H., & Biederman, R. W. (2011). Echodetection of disseminated endocardial vegetations in a patient with active IV drug abuse. *Echocardiography (Mount Kisco, N.Y.)*, 28(4), E72-E75. doi:10.1111/j.1540-8175.2010.01319.x
- Bor, D. H., Woolhandler, S., Nardin, R., Bruschi, J., & Himmelstein, D. U. (2013). Infective endocarditis in the U.S., 1998-2009: A nationwide study. *Plos One*, 8(3), e60033. doi:10.1371/journal.pone.0060033
- Centers for Disease Control and Prevention. (2016). Increases in drug and opioid overdose deaths—United States, 2000–2014. Retrieved from <http://www.cdc.gov/mmwr>
- Evans, C. F., & Gammie, J. S. (2011). State of the art: surgical management of mitral valve infective endocarditis. *Seminars in Thoracic and Cardiovascular Surgery*, 23(2), 240. doi:10.1053/j.semtcvs.2011.07.005
- Kim, J. B., Ejiro, J. I., Yammine, M., Ando, M., Camuso, J. M., Youngster, I., & Sundt, I. M. (2016). Acquired: surgical outcomes of infective endocarditis among intravenous drug users. *The Journal of Thoracic and Cardiovascular Surgery*, doi:10.1016/j.jtcvs.2016.02.072
- McCance, K.L., Huether, S.E. (2014). Pathophysiology: The biologic basis for disease in adults and children (7th ed.). St. Louis, MO: Elsevier/Mosby.
- Mikolaj, J., & Wilner, M. (2012). Naturopathic management of infections of the heart and their sequelae. *Townsend Letter*, (346), 57.
- Noel, N., & Naheed, Z. (2013). Hypertrophic cardiomyopathy: role of current recommendations by the american heart association for infective endocarditis. *Pediatric Cardiology*, 34(3), 709-711. doi:10.1007/s00246-012-0324-6
- Pant, S., Patel, N., Deshmukh, A., Golwala, H., Patel, N., Badheka, A., Metha, J. (2015). Trends in infective endocarditis incidence microbiology, and valve replacement in the United States from 2000 to 2011. *Journal of The American College of Cardiology*, 65(19).
- Pierce, D., Calkins, B. C., & Thornton, K. (2012). Infectious endocarditis: diagnosis and treatment. *American Family Physician*, 85(10), 981-986
- Sabe, M. A., Shrestha, N. K., & Menon, V. (2013). Contemporary drug treatment of infective endocarditis. *American Journal Of Cardiovascular Drugs: Drugs, Devices, And Other Interventions*, 13(4), 251-258. doi:10.1007/s40256-013-0015-6



OTTERBEIN  
UNIVERSITY